

Echinococcosis in Alaska

Introduction

Echinococcosis results from infection with parasites of the genus *Echinococcus*. Species of this cestode can be found worldwide. Human cases of cystic echinococcosis (infection with *Echinococcus granulosus*) have been reported throughout Alaska, except in the Aleutians. Cases of alveolar echinococcosis (infection with *E. multilocularis*) have been reported only from St. Lawrence Island and the North Slope areas.

Lifecycle and Pathogenesis

Echinococcus spp. lifecycles may involve many different hosts (Figure 1). In Alaska, intermediate hosts for *E. granulosus* are moose or caribou, and for *E. multilocularis*, voles. For either species of *Echinococcus*, canids – whether pets or wild animals such as foxes or wolves – serve as definitive hosts. Canids are infected by eating echinococcal cysts from intermediate host viscera. Humans are infected by ingesting eggs that are shed in the feces of infected canids.

Once ingested, eggs hatch and release embryos into the small intestine that penetrate the mucosa and disseminate throughout the body via venous and lymphatic systems. Embryos typically lodge in liver or lungs, forming cysts that enlarge concentrically and can attain large sizes before becoming symptomatic or being diagnosed. Cysts may rupture and, if in the lung, are sometimes expectorated; or, if in the abdomen, may seed surrounding tissues resulting in the development of secondary cysts.

Diagnosis

Echinococcal cysts may present as space-occupying lesions that cause symptoms referred to the gastrointestinal or respiratory systems; or they may cause no symptoms and only be discovered incidentally.¹ Diagnoses usually require ultrasound, CT, or MRI technology. Diagnoses can also be confirmed by examining cyst tissue or contents for evidence of the parasite. CDC (Centers for Disease Control and Prevention) can assist in identification and can evaluate sera for various *Echinococcus* antigens. Serological testing has marginal sensitivity and predictive value and should be considered an adjunct method of diagnosis.

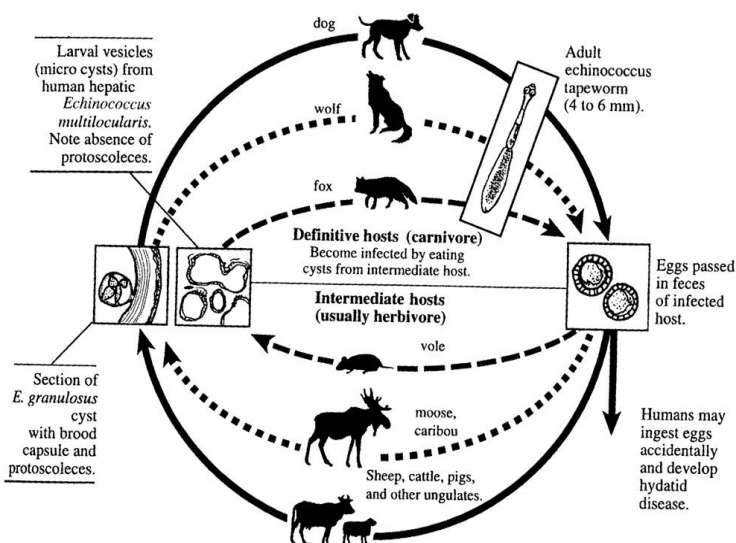


Figure 1. Lifecycle of *Echinococcus* spp.

Reprinted from "Hydatid Disease," Tempest B, Wilson JF, p. 93. In Galloway JM, Goldberg BW, Alpert JS, eds. *Primary Care of Native American Patients: Diagnosis, Therapy, and Epidemiology*, Butterworth-Heinemann, 1999, with permission from Elsevier Science.

Treatment

Empirical evidence from case reviews in Alaska and Canada suggested that asymptomatic *E. granulosus* cysts could be managed medically.²⁻⁶ Treatment of either form of echinococcosis should be tailored to an individual case and may include a combination of medical and surgical management depending on the location of the cyst(s) and the clinical presentation.

Human Cases in Alaska

Since the 1950s, over 300 cases of echinococcosis were reported to the Section of Epidemiology. Most cases were among persons from St. Lawrence Island or other rural parts of the State. Data have been summarized elsewhere.^{1,2,4}

Since 1990, only eight cases of *E. granulosus* and no cases of *E. multilocularis* have been reported. Because cases may be asymptomatic, the actual number of infections could be higher. Of the eight cases reported, the average age of patients was 35 years (range 13-97 years). Half of the patients were female, and 63% (5 of 8) were Alaska Native. Four cases were reported in Anchorage/Mat-Su Boroughs; two in the northwestern region of Alaska; and one each in the interior and southeastern regions.

Recommendations

- Human echinococcosis is a sporadic disease in Alaska. The best method of preventing infection is by interrupting the parasite's lifecycle.
 - Wash hands well after contact with dogs or items that may be contaminated with dog feces.
 - Prevent dogs from eating viscera of potentially infected animals.
 - Meat from hoofstock infected with *Echinococcus* is safe to eat; cook thoroughly and avoid eating organs with cysts.
 - Infections in dogs can be treated with praziquantel.
- Echinococcosis is a reportable public health condition for healthcare providers and laboratories. Reports can be made directly to the Section of Epidemiology at (907) 269-8000 during business hours and (800) 478-0084 after hours. Epidemiology can also facilitate submission of diagnostic specimens to CDC.

Photos of echinococcosis in wildlife can be seen at www.state.ak.us/local/akpages/FISH.GAME/wildlife/region5/guide/intro.htm (Alaska Department of Fish and Game).

References

- Tempest B, Wilson JF. Hydatid Disease. Galloway JM, Goldberg BW, Alpert JS, eds. *Primary Care of Native American Patients: Diagnosis, Therapy, and Epidemiology*. Boston, MA: Butterworth-Heinemann. 1999;91-101.
- Wilson JF, Diddams AC, Rausch RL. Cystic hydatid disease in Alaska: a review of 101 autochthonous cases of *Echinococcus granulosus* infection. *Am Rev Resp Dis* 1968;98(1):1-15.
- Meltzer H, Kovacs L, Orford T, Matas M. Echinococcosis in North American Indians and Eskimos. *Can Med Assn J* 1956;75:121-128.
- Pinch LW, Wilson JF. Non-surgical management of cystic hydatid disease in Alaska: a review of 30 cases of *Echinococcus granulosus* infection treated without operation. *Ann Surg* 1973;178(1):45-48.
- Lamy AL, Cameron BH, LeBlanc JG, et al. Giant hydatid lung cysts in the Canadian Northwest: outcome of conservative treatment in three children. *J Ped Surg* 1993;28(9):1140-1143.
- Finlay JC, Speert DP. Sylvatic hydatid disease in children: case reports and review of endemic *Echinococcus granulosus* infection in Canada and Alaska. *Ped Infect Dis J* 1992;11(4):322-326.